

# A Narrative Review on Modern Wound Dressing for Diabetes Mellitus Wound

Thandar Soe Sumaiyah Jamaludin<sup>1</sup>, Mohd Said Nurumal<sup>1\*</sup>, Sanisah Saidi<sup>1</sup>, Muhammad Kamil Che Hasan<sup>1</sup>, Nurezzatul Faseha Mohd Said<sup>2</sup>, Nor Hafizah Samsudin<sup>2</sup> & Chong Mei Chan<sup>3</sup>

<sup>1</sup>*Kulliyah of Nursing, International Islamic University Malaysia, Pahang, Malaysia.*

<sup>2</sup>*National Heart Institute of Malaysia, Kuala Lumpur, Malaysia.*

<sup>3</sup>*Department of Nursing, Universiti Malaya, Kuala Lumpur, Malaysia.*

## ABSTRACT

**Introduction:** Diabetic foot is a wide-ranging term for foot disorders includes infection, ulceration, or destruction of deep tissue due to peripheral neuropathy and ischemia from peripheral vascular disease. Wound dressings play a significant part in the treatment of diabetic foot ulcer (DFU). Modern wound dressing which is commonly known as the moist wound dressing can be better optional than the conservative one for the DFU. **Aim:** This study aimed to review the available articles on modern wound dressing for diabetes mellitus wound. **Method:** A total of six articles were reviewed and explained under the findings and discussion part of this study. The published articles from the year 2008 onwards are included in this narrative review. **Result:** Overall, it is evident that using of modern wound dressing can make sure excellent wound surroundings, avoid complications, improvement of quality of life of patients and aid the healing of DFU providing that the patient's glycemic level is controlled. **Conclusion:** The process of wound healing in DFU is not static and it requires an appropriate environment at each stage of the healing process. And also a reasonable approach to the selection of dressing for certain types of wounds should be clarified. However, further study needs to be carried out to prove the current finding.

**Keywords:** Diabetes Mellitus, Diabetic foot ulcer, Modern dressing

## INTRODUCTION

Diabetes mellitus is a chronic disease caused by inheritance and not sufficient pancreatic insulin production, but also by the ineffectiveness of the insulin produced in our body. Diabetes mellitus wound is a broad spectrum term which includes infection and ulceration. Among the diabetes wound, diabetic foot ulcer (DFU) is very common in people living with diabetes mellitus and it accounts for about 50% of non-traumatic amputations throughout the world (1). The wound dressing is an integral part of the management of

the DFU.

Malaysia has seen a surge of the prevalence of Diabetes mellitus with the latest number at 1 in 5 adults in Malaysia has diabetes based on National Health and Morbidity Survey (NHMS) 2019 which was increasing trend compared to the earlier survey (2). The DFU is a wide-ranging term for foot disorders includes infection, ulceration or destruction of deep tissue due to peripheral neuropathy and ischemia from peripheral vascular disease. Diabetic foot ulcers require ample care and need time to heal. A foot ulcer is one of the complications of diabetes mellitus and also the major causes of morbidity in a patient who have diabetes mellitus (1). Thus, wound dressings play a vital role in DFU management.

---

\* Corresponding author:

**Associate Professor Dr. Mohd Said Nurumal**

Department of Critical Care Nursing,  
Kulliyah of Nursing,  
International Islamic University Malaysia,  
Jalan Sultan Ahmad Shah, Bandar Indera Mahkota,  
25200, Kuantan, Pahang Darul Makmur, Malaysia.

Email: : mohdsaid@iiu.edu.my/  
sumaiyahSJ@gmail.com  
Tel no: +609-5707288

The wounds are classified as open or closed. An open wound is a break in the skin or a mucous membrane whereas a closed wound involves underlying tissues without a break in the skin or a mucous membrane. There are four principles of diabetic wound management to enhance the healing process. The principles include basic wound preparation, wound protection, wound

bandage, and wound oxygenation. The modern wound dressing or commonly known as a moist wound dressing can be better optional than the conservative ones. The modern dressing can keep humid environment balanced with a wound surface. In the modern wound dressing, a bioactive agent that is added at the dressing can increase the healing rate of the wound. Moreover, it can subjugate wound infection caused by the pathogens, and also capable to prevent it.

The modern wound dressing includes films, hydrogels, hydrocolloids, foams, alginates and hydrofibers. Hydrogels are preparations that contain up to 95% water along with organic additives such as pectin and starch, or gelling agents. Commonly, a tube or syringe is used to place the gel in the wound. Hydrogels can give moisture to the wounds as well as absorb excess wound exudates. They are used especially for dry wounds to facilitate autolytic debridement. The dressing has to change every day for debridement. However, the dressing should be changed every 2-3 days during granulation phase (3). Hydrocolloids dressing which is made of polyurethane film or foam which having self-adhesive mass made of elastomers and adhesives along with particles that can swell to absorb a large amount of exudates. Hydrocolloids are commonly used for superficial wounds with little exudates to promote granulation of epithelization. Hydrocolloids dressing should be changed every 3-5 days depends on the amount of exudates.

Furthermore, foam dressing is made of non-irritating polyurethane foam which the surfaces may be coated with silicone or heat-treated. Usually, foam is used in moderate or strong exuding wounds to promote granulation and epithelization. The foam can be placed on the wound up to 7 days depending on the amount of exudates. Alginate dressing consists of a loose dressing structure that made up of fibers that are composed from red or brown algae. Alginate commonly used for deep, jagged or heavily exuding wounds. The functions of alginate are to cleanse a wound and to promote granulation. Like other dressing, the alginate should be placed on the wound up to 5 days depends on the amount of exudates. Hydrofibers dressing or also known as aqua fibers are consists of sodium carboxyl cellulose. Hydrofibers products may be used for large amounts of exudates at large wounds to promote granulation as well as to cleanse the wound.

On the other hand, hyperbaric oxygen therapy (HBOT) is commonly used along with the modern wound dressing to promote the wound healing

process in DFU (4). It is rapidly gaining popularity as an effective adjuvant therapy by enhancing wound epithelisation and fastening the process of wound closure in DFU management although unknown which patients are likely to benefit from HBOT and which patients are not (5). However, management of DFU demands a multi-team approach and often diagnosed at primary health centres and general practice. Thus, this narrative review aimed at the analysis of available research that focuses on the effect of modern wound dressing on DFU management.

## METHODS

Six articles were reviewed in this study. The articles were searched through Science Direct, Pro-Quest Health and PubMed online databases. The articles search strategy with search mode 'find all my search terms' within the full text of the articles including patents while limiting the result for full text and peer-reviewed without putting any specific publication. The range of published data that has been included in this review was from the year 2010 onwards and limited to the English language only. The journal subset being set for all and accepting from both male and female. The searching keywords are diabetes mellitus, diabetic foot ulcer, and modern wound dressing. Also, Boolean logic (AND) is used to combine the search terms.

In this narrative review, the authors aimed to include only original articles so that the data can be presented completely and facilitate the aim of this review. Although this is a narrative review, the literature search process was systematically carried out by using PRISMA flow as shown in figure 1. The author and co-authors identified the full-text articles and read those articles independently based on the criteria that set for this narrative review. Since the published intervention studies are included for review in this study, the critical appraisal skill program (CASP) (2018) tool was used for the quality critical appraisal assessment (6).

The search strategy using the identified keyword for this narrative review retrieved 850 articles at the beginning from the selected databases. A total of 750 articles were excluded due to they were not relevant for this study. After screening and selecting the eligible articles for this review, six articles were chosen and analysed in this narrative review. Figure 1 shows the details process of this narrative review.

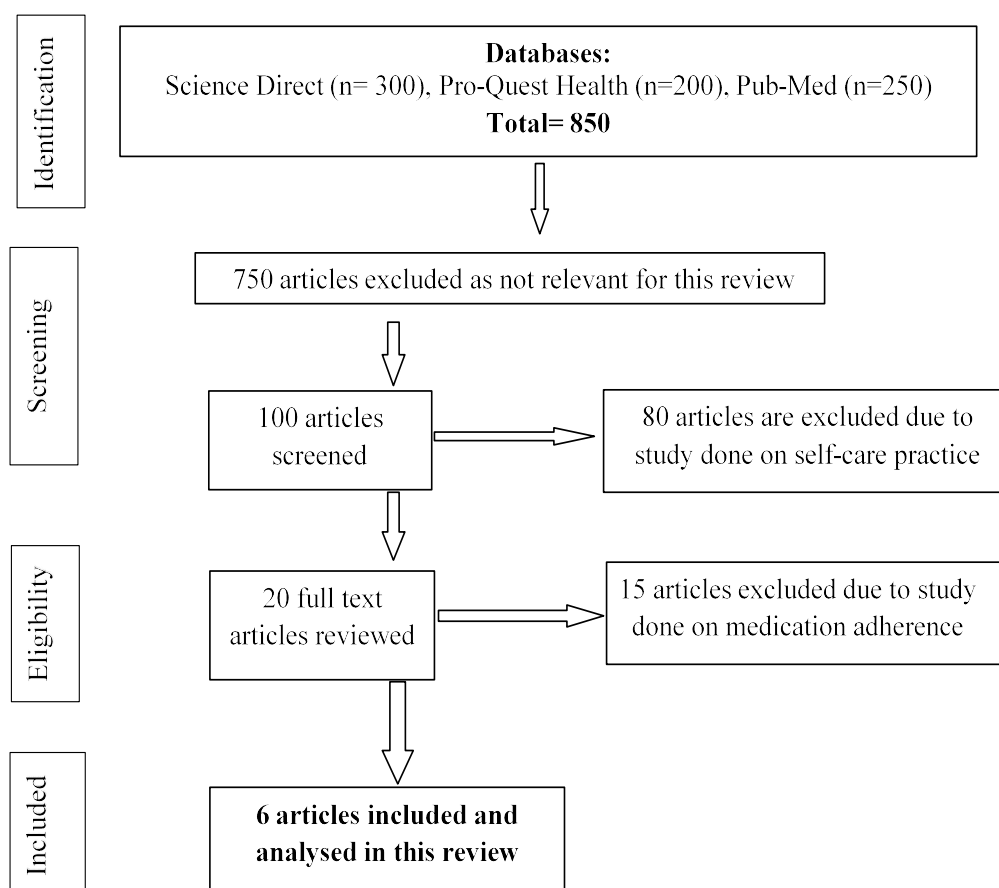


Figure 1. The literature search flow

## FINDINGS

Based on the six articles, several outcomes have been explained by the authors to show which type of modern dressing is effective for DFU management. The first study included in this review was done on the effectiveness of vacuum-assisted closure therapy (VACT) with conventional povidone iodine dressing (CTPID) in the management of DFU (7). They have used those two methods for two groups of patients for two weeks. At the end of the study, the mean surface area of the ulcer treated with VACT and CTPID was reduced from 11.21cm<sup>2</sup> to 8.6cm<sup>2</sup> and 12.24cm<sup>2</sup> to 11.30 cm<sup>2</sup>, respectively ( $p = 0.029$ ). The mechanism of VACT is not thoroughly clear. However, the evidence put forward that interstitial pressure gets decreased due to edema reduction, which positively influences lymphatic drainage, oxygen, and also nutrient availability in the DFU (7).

The second study was done on the effect of nanocrystalline silver ion dressings and its comparison with standard normal saline dressings in DFU (8). With a total of 30 patients aged between 18-75 years and been diagnosed with Diabetes Mellitus (DM) were included in the study. They were equally divided which is 15 patients into a

study group and control group randomly. The study group were treated with nanocrystalline silver ion dressings which were changed every 2 to 3 days while in the control group, normal saline soaked gauzes were used which were changed daily. The wound was assessed for wound discharge, granulation tissue, changes in the size of the wound and the presence of slough was recorded. Throughout the investigation, each patient received conventional care and supportive of wound and blood sugar was controlled by insulin and oral hyperglycemia and strict euglycemia were planned. Moreover, broad-spectrum systemic antibiotics were administered to all patients. Thus, the finding showed in this study was the study group had better outcomes with 10 patients (66.7%) being complete responders as compared to control group with 5 patients (33.3%) were complete responders. The wound discharge changed from purulent to serous, faster in the study group and also significantly better for granulation tissue formation and slough assessment.

The third study of this narrative review was about an investigation of the effect of Beri-honey-impregnated dressing on DFU and compare it with normal saline dressing (9). The total patient of this study was three hundred and forty-eight with Wagner's grade 1 and 2 ulcers were included. They

were divided into two groups; Group A with 179 patients treated with honey dressing while Group B with 169 patients treated by normal saline dressing by using a simple randomized method which is computer-generated random numbers. The finding measures were calculated in the terms of proportion of wounds completely healed (primary outcome), wound healing time and deterioration of wounds. With a maximum of 120 days, the patients were followed-up. As a result, 136 patient (75.97%) treated with honey dressing and 97 patient (57.39%) treated with normal saline dressing were completely healed, while the number of incompletely healed wounds, was significantly less in the honey treated group as compared to a saline-treated group, 32 (17.87%) vs. 53 (31.6%), respectively. In 6 to 120 days, the mean wound healing time was 18.00 in Group A while 7 to 120 days, the mean wound healing time was 29.00 in Group B.

The fourth study was done on modern wound care for the poor: a randomized clinical trial comparing the vacuum system with conventional saline-soaked gauze dressings (10). The objective of this study was to determine whether a simple homemade wound vacuum-dressing (HM-VAC) is an appropriate alternative to the use of conventional saline-soaked gauze dressings (WET) for the treatment of complex wounds in a resource-poor hospital. In this study, 49 patients were analyzed to compare HM-VAC and WET dressings. The main outcome measure was the duration of wound healing has been completed. Also, the costs of both methods were calculated. Forty-nine patients were recruited consecutively from January 2007 to June 2007. The inclusion criteria for this study was the patient had a single wound at the time he or she included in the study. Patients included in the study when surgical debridement has been decided to perform. Then, patients were randomized by a sealed envelope to receive treatment with either WET dressing or the HM-VAC techniques.

The first endpoint determined was the time of wound healing (in days) until wound closure or split-skin grafting was possible. The outcome of the wound healing with HM-VAC and the WET dressing was analyzed during the treatment and 30 days after successful closure of the wound. The wounds that did not need skin grafting were judged to be healed if there are no signs of redness, heat, edema, discharge or wound dehiscence and have no fever. The wound was considered to have healed completely when all these indicators were negative. The results of this propose that wound management with the HM-VAC is appropriate in a LDC inpatient facility with excellent short-term

results. The biggest benefit of the HM-VAC is the 41% reduction in the median wound-healing time compared to the WET dressing technique. The materials needed to assemble the HM-VAC are easily available, and the technique can be promptly adopted by local surgeons.

The fifth study was about a comparison of conventional pyodine dressing with honey dressing for the treatment of diabetic foot ulcers (11). The objective of their study was to analyze the conventional pyodine dressing with honey dressing in terms of recovery time and outcome which healed or ended up with amputation in DFU. They used quasi-experimental method. All Wegner's grade I-IV, unilateral diabetic foot ulcer patients were admitted and their blood sugar profile, cardiac and renal status were examined. Patients were categorized to group A and group B with simple convenience method. After appropriate surgical wound debridement, group A was treated with the conventional daily pyodine dressing while group B was treated with daily honey application. During 10 weeks follow up period, their recovery time, outcome were noted and recorded.

Their result was a total of 100 patients with 50 patients in each group A and B were enrolled in the study with mean age 56+8.0 years and male to female ratio of 1.7:1. Recovery time was significantly faster in the Group B which was honey dressing compared to the group A which was conventional Pyodine dressing with a p-value of <0.0001. Rate of healing was 69% and amputation rate was 31% as a whole. Healing rate was 66% in the Group A while 72% in the group B. Rates of amputation were 34% and 28% in the group A and B respectively with no statistical significance with a p-value of 0.6658.

The last article reviewed in this study was about a comparative study between honey and povidone iodine as dressing solution for Wagner Type II DFU (12). They conducted the study by using a prospective study to compare the effects of honey dressing for Wagner's grade II diabetic foot ulcers with controlled dressing group which was povidone-iodine followed by normal saline. They conducted the study at Hospital Universiti Sains Malaysia (HUSM). All non-insulin-dependent diabetes mellitus patients with Wagner grade II ulcers who were admitted for surgery were included if the inclusion criteria have met during the study period. Their inclusion criteria were age between 35 to 65 years old, transcutaneous oxygen tension of more than 30 mmHg and serum albumin level of more than 35 g/dl were fulfilled. The patients were randomized into two study

group in which the first group was assigned with honey dressing group and the second group was standard dressing group which was wound will be covered by povidone-soaked gauze. All patients took ample antibiotics and the ulcers were debrided surgically as well as the tissue specimens were taken during the debridement to send for culture and sensitivity testing. The dressings were carried out daily. The results for their study was the wound, in the beginning, harboring with *Streptococcus*, *Staphylococcus*, *Acinobacter*, *Proteus* and *Eschrichia coli* become negative culture at the end of treatment for control group. However, wound that infected by *Pseudomonas*, *Enterococcus* and mixed organisms still infected until the end of the study. In honey dressing group, *Staphylococcus* or *Streptococcus* ultimately become negative culture at the end of treatment while those harboring *Bacteroids*, *Enterococcus* and mixed infections remained infected. To be ready for surgical closure, wounds in control group took a mean time of 15.4 days while in honey dressing group; the wounds need a mean time 14.4 days to complete the same status. Then, all patients in the honey group dressing felt less pain compared to the control group during dressing. Also, oedema and foul-smelling discharges upgraded faster compared to control group dressing.

## DISCUSSION

Based on the literature findings, the patients who were suffering from DFU can be treated with proper management of wound care by using modern dressing. Also, to promote wound healing can be done by selecting an appropriate dressing with timely replacement. Various modes of treatment and wound dressings were used but still, the treatment failure rate is very high and many patients still end up with limb amputations (8).

Since the studies were focused on modern dressing treatment for DFU, many researchers conducted the study by comparing the type of dressings such as a comparison between honey and povidone-iodine, honey and normal saline, vacuum-assisted closure therapy (VACT), simple homemade wound vacuum dressing system (HM-VAC) and povidone-iodine and others (7-12). By using the VACT in DFU, the mean area of the ulcer was decreased compared to povidone-iodine dressing (7).

However, the research found that the use of povidone-iodine has been restricted due to its cytotoxicity (7). Their study recommended that negative pressure give positive impact in increasing vascular diameter, volume and velocity of blood flow by using VACT for DFU (7). Similar to this another study also conducted by using HM-

VAC compared with saline-soaked gauze dressing (10). Their study stated that HM-VAC was the greatest benefit in reducing the median wound healing time compared to the WET dressing techniques. Furthermore, the larger number of initial wound closures in the vacuum group can be related to promoting tissue proliferation and wound contractures (10). However, both studies still need to improve because the researchers did not focus on the cost treatment regarding vacuum dressing. Hence, the vacuum dressing not common use in undeveloped countries due to the extremely high cost of devices. Besides, the researchers also obtained short term results only for their studies and their interpretation of the results is complicated by the diversity of the causes of the wound analyzes in the present study. Nevertheless, they decided to treat both acute and chronic wound with vacuum therapy.

The next study was about honey dressing compared with normal saline, povidone and pyodine (9-11). The researcher described that honey dressing was more effective in the management of DFU compared to normal saline and povidone-iodine dressing (9). Another researcher pointed out that honey able to absorb water from interstitial tissue through its higher osmolarity and it may turn improved local lymphatic drainage and blood circulation (10). Dressing procedure of honey was less painful due to the ability of the honey to maintain the moisture of the wound without adhesion to the granulating surface. Also, it has been shown to have a direct effect on reducing pain in burn wounds. Another study stated honey contains hyperosmotic sugar contents and it is sterile and thus prevents bacteria growth at the wound (11). It also has thermolabile inhibin which due to low pH and hygroscopic qualities acts as antimicrobial agents. It was started widely for chronic wounds, burns, chronic leg ulcers, decubitus ulcers and radiation necrosis after the discovery of inhibin. Honey can help in healing processes and promotes epithelization.

Based on the above studies, it can be shown that honey dressing is the best option for the management of wound care especially DFU. The findings suggest that wound dressing with honey is cheaper and hence it does provide an economical and safe alternative for the management of foot ulcer in diabetic patients (9-11). However, it is recommended that using the best honey product in treating a wound to fasten the healing process of the wound (9-10).

The other study highlighted using nanocrystalline silver showed faster healing compared to

conventional normal saline soaked dressing in DFU with the early disappearance of discharge and slough and early appearance of granulation tissue (8). The silver ion promotes a faster wound contraction due to accelerated proliferation and differentiation of fibroblast into myofibroblast (8). Similar to this, a study was done on nanocrystalline silver (nAg), manuka honey (MH), and conventional dressing in healing DFU (13). They found that the ulcer size reduction rate was potentially higher in the nAg group (97.45%) than the MH group (86.21%) and the conventional group (75.17%). Furthermore, nAg showed a greater rate of microorganism reduction although it was not significant in bacteriology test (13). Therefore, nAg alginate was potentially superior to MH and conventional dressing in healing DFU in terms of ulcer size reduction rate.

Consequently, the DFU is a crucial event in the life of a people living with diabetic and a marker of serious disease and comorbidities. If there is no proper management, the DFU can rapidly deteriorate and leading to amputation of the affected limb. The proper management of DFU included as wound care by using modern wound dressing, patient education on the care of the foot, diabetic care diet, good glycaemic control, offloading, debridement, infection control, patient knowledge on diabetic, practice on medication adherence and adequate perfusion was vital in the management of diabetic foot ulceration. The person with DFU, need to understand about the proper management. Because having a good or poor knowledge level on diabetes medication does not guarantee their health-seeking practice of medication adherence (14). Thus, by using proper management in DFU will improve the quality of life of people living with diabetes mellitus.

## CONCLUSION

Diabetes mellitus is a serious incapacitates and deadly disease which now has reached epidemic proportions. The prevalence rates are predicted to go even higher in the future. The DFU is one of the complications of diabetes mellitus and also the major causes of morbidity in people living with diabetes mellitus. The most common complication of DFU is amputation of the limbs. Consequently, amputation gives a negative impact on the quality of life of the patient. That is why prevention plays an important role to decrease the limb amputation rate. Regular examination, awareness, precautions and appropriate treatment of minor injuries can significantly decrease the incidence of DFU. Thus, wound care also play a vital role in DFU management. Wound care done by modern dressing using the humid principle shows that

there is tissue change occurred in some examination wound components. The components are decreasing of wound size, wound depth, granulation percentage, declining of the number of necrosis tissue as well as the amount of the liquid appearing. An ideal dressing is expected to possess the capacity of moisture balance, promote oxygen exchange, isolate proteases, stimulate growth factors, prevent infection, facilitate autolytic debridement, and promote the production of granulation tissue and re-epithelialization. Although the benefits of the available modern wound dressing on the wound healing process of DFU are described in this study, there is a need for future study needs to be carried out to confirm the results. However, the main treatment of the underlying diseases is the main prerequisite for DFU.

These actions are similar and, nevertheless, might be different in terms of the concepts, of which they integrate the patients' autonomy into the nurse-patient relationship. Bunkenborg et al. (2), for instance, imply that nurses are only able to meet the patients' best interests when they can play the role of patient advocate. For example, nurses should provide a patient with the information required for the patient to make informed choices support his/her right to make informed choices and support the patient throughout the decision-making process and outcomes. Additionally, nurses should be attentive to the patient's needs, expressed wishes and preferences, as well as ensure that these are known and implemented by other nurses and healthcare providers (3).

As 'front liners' in healthcare teams, nurses should act as advocates or mediators in terms of inculcating advocacy into the practice and toward their patients, families, community and their organisation (4). In other words, nurses contribute to health service planning and decision-making and advocate health policy changes. This is because nurses are responsible for the delivery of the majority of patients' care and are in a position to influence patient care outcomes (5). Similarly, nurses' relationships with patients and their families enables them to appreciate their health needs, expectations of healthcare and responses to healthcare services (6).

## CONFLICT OF INTEREST

The authors declare no conflict of interest.

## REFERENCES

1. Burns S & Jan YK. Diabetic foot ulceration and amputation. *Rehabil Med* 2012;1-20 Diabetes mellitus. Retrieved from <http://www.who.int/mediacentre/factsheets/fs138/en/>
2. Institute for Public Health. National Health and Morbidity Survey (NHMS) 2019: Non-communicable diseases, healthcare demand, and health literacy: Key Findings. Malaysia: National Institutes of Health (NIH). 2020.
3. Dissemmond J, Augustin M, Eming SA, Goerge T, Horn T, Karrer S, Stücker M. Modern wound care - Practical aspects of non-interventional topical treatment of patients with chronic wounds. *JDDG - Journal of the German Society of Dermatology*. 2014; 12(7), 541-555. <https://doi.org/10.1111/ddg.12351>
4. Sunkari VG. et al., "Hyperbaric oxygen therapy activates hypoxia-inducible factor 1 (HIF-1), which contributes to improved wound healing in diabetic mice: HBO therapy activates HIF," *Wound Repair Regen.*, vol. 23, no. 1, pp. 98-103, Jan. 2015.
5. Ahdiah N, Junaidi G, Haris S N, Jamaludin TSS. Effectiveness of Hyperbaric Oxygen Therapy for Wound Healing in Patient with Diabetic Foot Ulcer: A Mini Re-view. *International Journal of Care Scholars* 2019;2(1).
6. Critical Appraisal Skills Program. (2018). Accessed from <http://creativecommons.org/licenses/by-nc-sa/3.0/> retrieved on 13/10/2019.
7. Kajagar B, Joshi K. Efficacy of vacuum-assisted closure therapy versus conventional povidone Iodine dressing in the management of diabetic foot ulcers: A randomized control trial. *Int J Health Sciences Research*. 2017;7(5).
8. Gupta, V., Kakkar, G., Gill, A. S., Gill, C. S., & Gupta, M. (2018). Comparative Study of Nanocrystalline Silver Ion Dressings with Normal Saline Dressings in Diabetic Foot Ulcers. *Journal of Clinical & Diagnostic Research*, 12(6).
9. Imran, M., Hussain, M. B., & Baig, M. (2015). A randomized, controlled clinical trial of honey-impregnated dressing for treating diabetic foot ulcer. *J Coll Physicians Surg Pak*, 25(10), 721-725.
10. Perez D, Bramkamp M, Exe C, von Ruden C, Ziegler A. Modern wound care for the poor: a randomized clinical trial comparing the vacuum system with conventional saline-soaked gauze dressings. *The American journal of surgery*. 2010;199(1):14-20.
11. Jan WA, Shah H, Khan M, Fayaz M, Ullah N. Comparison of conventional pyodine dressing with honey dressing for the treatment of diabetic foot ulcers. *Journal of Postgraduate Medical Institute (Peshawar-Pakistan)*. 2012;26(4).
12. Shukrimi A, Sulaiman A, Halim A, Azril A. A comparative study between honey and povidone iodine as dressing solution for Wagner type II diabetic foot ulcers. *Med J Malaysia*. 2008;63(1):44-6.
13. Tsang K-K, Kwong EW-Y, To TS-S, Chung JW-Y, Wong TK-S. A pilot randomized, controlled study of nanocrystalline silver, manuka honey, and conventional dressing in healing diabetic foot ulcer. *Evidence-Based Complementary and Alternative Medicine*. 2017.
14. Nurumal MS, Jamaludin TSS, Mohammad NM, Hasan MKC, Win KK. A review on knowledge of diabetes and practice of medication adherence among people living with diabetes mellitus. *International Journal of Care Scholars* 2020;3(1).