

CASE REPORT

STRIDOR, IS IT ALWAYS LARYNGOMALACIA IN AN INFANT?

Bazlin Ramly, Asim Khan

**Paediatric Department, Letterkenny University Hospital,
Co Donegal, Ireland.**

Abstract

OC, a 3 week old infant presented with acute episode of shortness of breath associated with cough and was diagnosed as bronchiolitis initially but readmitted at the age of 4 weeks and 6 weeks with almost similar complaint but in addition with worsening stridor. She was diagnosed to have laryngomalacia. The stridor was biphasic in nature with a more pronounced inspiratory component and was exacerbated by agitation and supine positioning. Initial bedside fiberoptic examination by otolaryngology did not reveal any clear structural abnormalities, but it was unable to assess beyond the vocal cords. Due to the worsening respiratory distress and clinician/ parental concern, OC was then referred to ENT team in tertiary hospital to seek the underlying problem. She had undergone microlaryngoscopy and bronchoscopy (MLB) which showed subglottic haemangioma and proceeded with magnetic resonance imaging. She was commenced on Propranolol and she responded very well to the treatment. She is still under follow up and will be continued on Propranolol till the age of 18 months when she will be reassessed again.

Keywords: Stridor, Subglottic Haemangioma, Propranolol, Microlaryngoscopy and Bronchoscopy

Corresponding author: Dr Bazlin Ramly, Paediatric Registrar, Paediatric Department, Letterkenny University Hospital, Letterkenny, Co Donegal, Ireland

Tel: +353838399421

Email: mrcpch2016@gmail.com

Introduction

Haemangioma is the most common vascular neoplasm in children [1]. Overall, infantile haemangioma affects 4%-5% of the paediatric population, making them the most common type of head and neck tumour in children [2]. Haemangiomas are the congenital vascular lesions that undergo a phase of rapid growth that is initiated during the first few weeks to months of life,

followed by involution by about 1 year of age [3]. Congenital subglottic haemangiomas are rare and are a benign tumour of infancy. There is a higher prevalence in females with a female to male ratio of 2:1.

Case report

At the age of 3 weeks old, OC presented to us with an acute episode of shortness of

breath that was preceded with worsening cough. OC was well up to the day of presentation whereby she was born via spontaneous vaginal delivery at term with the weight of 3.2 kg. Antenatally and postnatally were uneventful. She was admitted under paediatric unit for a concern of worsening respiratory symptoms as the child was starting to have difficulty in feeding. Child was afebrile during this first admission as well as all the subsequent admissions. On examination, she was a thriving child. On auscultation of the lungs, there was minimal wheeze with equal air entry bilaterally. Other examinations were unremarkable except for a small haemangioma on the scalp which is 0.5 cm x 0.5 cm in size which had not increased in size. The diagnosis was bronchiolitis. It was just an overnight admission and the child was discharged home well the next day. About a week after, she presented again with breathing and feeding difficulty.

However, in addition to these symptoms the mother gave the history of the child having stridor after being discharged during the first admission and stridor had been worsening as well. OC was having harsh stridor and tachypnoea though saturation did not fall below 95% even without oxygen supplement. Her lungs were clear with equal air entry. Blood investigations that included full blood count, renal profile and C-reactive protein were done and were all normal. Due to the presentation, there was a concern of possible "croup" thus she was commenced on budesonide nebulisation and oral dose of dexamethasone. She responded to the medications very well as the stridor subsided eventually and the breathing effort was back to normal. However, due to her young age, she was then diagnosed to have laryngomalacia with possible viral infection causing the worsening stridor. Clinicians were not very convinced the medications

prescribed were therapeutic and were more convinced laryngomalacia sounded "worse" due to child being agitated. She was then discharged again.

Around 6 weeks of age, OC presented with worsening stridor and shortness of breath. Feeding was getting more difficult. Parents were getting more concerned as OC was not improving and breathing was getting much worse. Lungs were clear with equal air entry. She did not respond positively despite giving additional support with humidified high flow nasal cannula with oxygen. The stridor was biphasic in nature, with a more pronounced inspiratory component and was exacerbated by agitation and supine positioning. The diagnosis of laryngomalacia was re-evaluated and she was reassessed. OC was commenced on budesonide nebulisation and oral dexamethasone. Again all blood investigations were all normal. She responded very well to both medications. Due to this, OC was then referred to the paediatric otolaryngologist in a tertiary hospital with a concern of possible airway abnormalities below the vocal cord.

Initial flexible nasendoscopy did not reveal any structural abnormalities thus microlaryngoscopy and bronchoscopy (MLB) was performed. It revealed bilateral and circumferential subglottic haemangioma as in Figure 1. Subsequent magnetic resonance imaging (MRI) of the neck also revealed subglottic haemangioma as shown in the Figure 3. OC was then commenced on oral propranolol with initial dose of 1mg/kg/dose every 8 hours and was stepped up to 2mg/kg/dose every 8 hours. Prior to starting propranolol, OC underwent pre-treatment workup that included electrocardiography, echocardiography, baseline pulse, blood pressure and blood glucose. Significant improvements in stridor

and respiratory effort were noted after 72 hours after initiating propranolol therapy. After a week there was no more stridor noted. There were neither cardiac arrhythmias nor any side effects of propranolol. She was discharged home with propranolol. Repeat MLB after 1 month on

propranolol showed subglottis was normal. She is currently doing very well, attending the ward every 6-8 weeks to increase the dose in accordance with her weight. Propranolol will be continued provisionally till she is 18 months of age.

Figure 1. Bilateral and circumferential subglottic haemangioma on microlaryngoscopy and bronchoscopy (MLB). Arrows showing area of stenosis due to the enlarging haemangioma

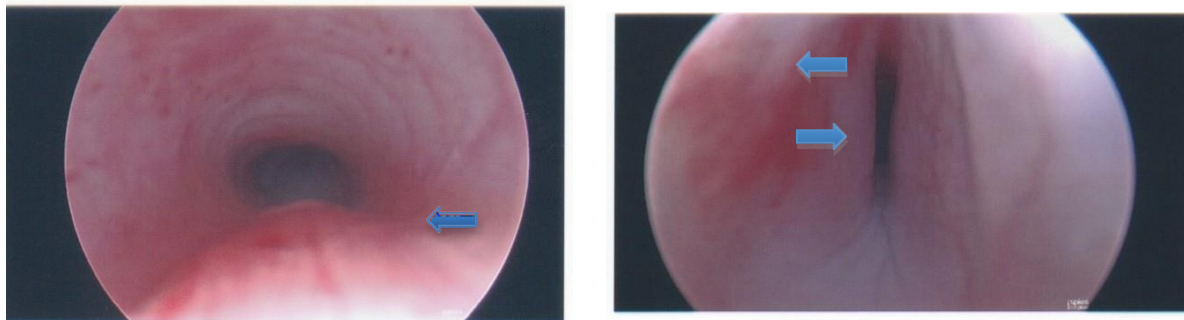
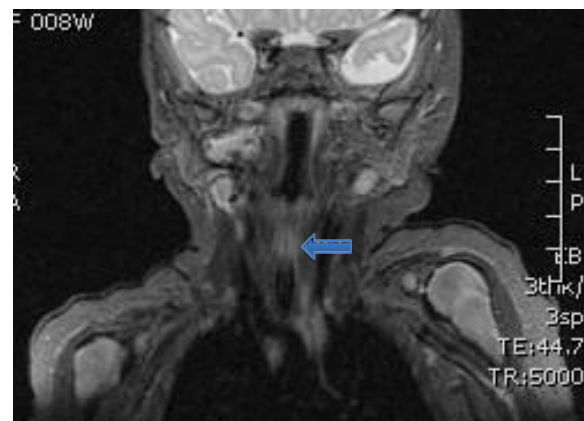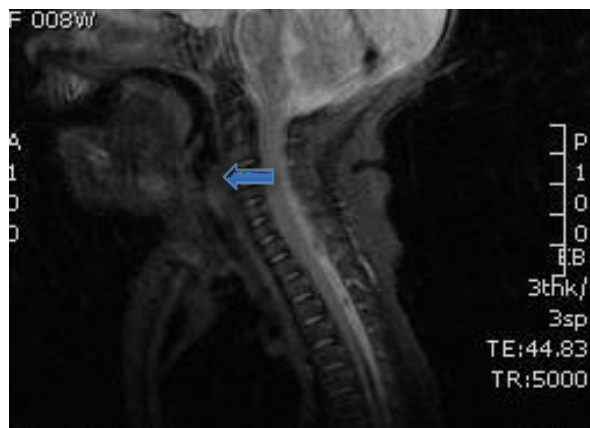


Figure 2. MRI finding: T2 hyperintense mass lesions showed by the arrows, most suggestive of haemangiomata. Lesions involved right parotid, parapharyngeal, submandibular, overlying manubrium sterni and also narrowing and mucosal hyperintensity of the subglottic airway which likely represents further haemangioma, although imaging of this lesion is suboptimal



Discussion

Although congenital subglottic haemangioma is a benign growth which accounts for only 1.5% of congenital abnormalities [4], it can cause severe

obstruction of the airway and can lead to respiratory failure and is therefore life-threatening [1, 5]. Subglottic haemangioma poses a great challenge to clinicians to evaluate the children for respiratory distress

due to its rarity and a mortality rate of close to 50% if left untreated [6].

During the earlier stage, a subglottic haemangioma is often mistaken for a more common condition such as croup, however, conservative treatments such as adrenaline and steroids are only transiently helpful [7]. Thus, patients who presented with “recurrent croup” should be the candidates for further evaluation of subglottic haemangioma especially when the episodes of respiratory distress are worsening and are not associated with fever or rhinorrhea [7]. Often, subglottic haemangioma occurs in isolation but the presence of cutaneous haemangioma may also suggest the presence of a subglottic haemangioma in children with respiratory distress [8]. In our case, the patient’s more prominent inspiratory component to her stridor led to the initial misdiagnosis of laryngomalacia.

Clinical diagnosis of subglottic haemangioma can be quite difficult to be made solely based upon thorough history taking and complete physical examination. Other modalities which include rigid endoscopy, microlaryngoscopy and bronchoscopy (MLB), computed tomography angiogram (CTA), and magnetic resonance imaging (MRI) are very useful in assisting clinicians to diagnose subglottic haemangioma.

There are multiple substantial reports with regards on the dramatic effect of oral propranolol on the size and volume of vascular masses [9,10]. Treatments for subglottic haemangioma have been advancing over the past decades. In 2008, a child with a nasal haemangioma was reported being treated with propranolol for an unrelated hypertrophic cardiomyopathy showed rapid regression of haemangioma within days of initiating propranolol [11].

Since then, propranolol has become the new first-line treatment for infantile haemangioma whereby previously the choices of treatments included systemic corticosteroids, intralesional steroids, carbon dioxide laser, tracheostomy and open surgical resection.

Conclusion

Subglottic haemangioma in infants can be fatal if it is not detected and diagnosed early as it can cause severe respiratory distress to these children. Once diagnosed, treatment with oral propranolol proves to have significant positive results.

References

- [1] Truong MT, Chang KW, Berk DR, Heerema-McKenney A, Bruckner AL. Propranolol for the treatment of a life-threatening subglottic and mediastinal infantile hemangioma. *J Pediatr.* 2010;156(2):335-8.
- [2] Haggstrom AM, Drolet BA, Baselga E, et al. Prospective study of infantile hemangiomas: clinical characteristics predicting complications and treatment. *J Pediatr.* 2006;118:882-7.
- [3] Ahmad SM, Soliman AM. Congenital anomalies of the larynx. *Otolaryngol Clin North Am* 2007; 40: 177.
- [4] Holinger PH, Brown WT. Congenital webs, cysts, laryngoceles and other anomalies of the larynx. *Ann Otol Rhinol Laryngol.* 1967;76:744-52.
- [5] Denoyelle F, Leboulanger N, Enjolras O, Harris R, Roger G,

- Garabedian EN. Role of Propranolol in the therapeutic strategy of infantile laryngotracheal hemangioma. *Int J Pediatr Otorhinolaryngol.* 2009;73(8):1168-72.
- [6] Ferguson CF, Flake CG. Subglottic haemangioma as a cause of respiratory obstruction in infants. *Ann Otol Rhinol Laryngol.* 1961;70:1095–112.
- [7] O-Lee TJ, Messner A. Subglottic hemangioma. *Otolaryngol Clin N Am.* 2008;41:903–11.
- [8] Orlow S, Isakoff M, Blei F. Increased risk of symptomatic hemangiomas of the airway in association with cutaneous hemangiomas in a “beard” distribution. *J Pediatr.* 1997;131:643–6.
- [9] Drolet BA, Esterly NB, Frieden IJ. Hemangiomas in children. *N Engl J Med.* 1999;341:173–181.
- [10] Nguyen J, Fay A. Pharmacologic therapy for periocular infantile hemangiomas: a review of the literature. *Semin Ophthalmol.* 2009;24:178–184.
- [11] Lopriore E, Markhorst DG. Diffuse neonatal haemangiomatosis: new views on diagnostic criteria and prognosis. *Acta Paediatr* 1999; 88:93.